

2020

Intoxicación accidental con Nerium oleander en lechería caprina en la Región Metropolitana de Santiago en Chile

Carlos Andrés Flores Olivares

Universidad Mayor, Santiago de Chile, carlos.flores@umayor.cl

Cristina Andrea Moraga Muñoz

Universidad Mayor, Santiago de Chile

Francisco López Eldredge

Universidad Mayor, Santiago de Chile

Isabel Pinto Morales

Universidad Mayor, Santiago de Chile

Lía Alejandra Navarrete Figueroa

Universidad Mayor, Santiago de Chile

See next page for additional authors

Follow this and additional works at: <https://ciencia.lasalle.edu.co/mv>



Part of the [Agriculture Commons](#), [Animal Sciences Commons](#), and the [Veterinary Medicine Commons](#)

Citación recomendada

Flores Olivares CA, Moraga Muñoz CA, López Eldredge F, Pinto Morales I, Navarrete Figueroa LA, Rodríguez Latorre CA, Peña Meza RJ y Sam Rodríguez S. Intoxicación accidental con Nerium oleander en lechería caprina en la Región Metropolitana de Santiago en Chile. Rev Med Vet. 2020;(39): 43-48. doi: <https://doi.org/10.19052/mv.vol1.iss39.4>

This Artículo is brought to you for free and open access by the Revistas científicas at Ciencia Unisalle. It has been accepted for inclusion in Revista de Medicina Veterinaria by an authorized editor of Ciencia Unisalle. For more information, please contact ciencia@lasalle.edu.co.

Intoxicación accidental con Nerium oleander en lechería caprina en la Región Metropolitana de Santiago en Chile

Autores

Carlos Andrés Flores Olivares, Cristina Andrea Moraga Muñoz, Francisco López Eldredge, Isabel Pinto Morales, Lía Alejandra Navarrete Figueroa, Constanza Andrea Rodríguez Latorre, Romina Javiera de María Peña Meza, and Susana Sam Rodríguez

Accidental Poisoning with *Nerium Oleander* in Dairy Goat in the Santiago Metropolitan Region in Chile*

Carlos Andrés Flores Olivares¹ / Cristina Andrea Moraga Muñoz² / Francisco López Eldredge³ /
Javiera Isabel Pinto Morales⁴ / Lía Alejandra Navarrete Figueroa⁵ / Constanza Andrea Rodríguez Latorre⁶ /
Romina Javiera de María Peña Meza⁷ / Susana Sam Rodríguez⁸

Abstract

A small dairy goat farm in central Chile stocked their troughs with ornamental plants and grasses, which were obtained after pruning the gardens of neighboring sectors. Twelve hours after the goats ingested this food, the farm registered a death toll of eight goats, all of which were adult females in their productive stage, before entering the milking parlor. The mortality episode lasted 84 hours and produced mortality and morbidity values of 48 and 54 percent, respectively (n = 52). During a visit to the farm, clinic inspections, autopsies, and sample tissues were obtained for microscopic analysis (the tissues specimens were fixed in 10% buffered formaldehyde solution). The clinic inspection and microscopic analysis both confirmed that the animals had cardiovascular disease. The lesions were compatible with those produced by cardiac glycosides. During the site visit, *Nerium oleander* was found in the troughs, which suggested that the animals were poisoned by eating this plant. There was a high presence of this plant in the poisoned area, and it was not associated with the mortality episode before the on-site visit, which indicates that the authors should conduct training and inform producers about the handling and feeding of their animals.

Keywords: *Nerium oleander*, glycosides, small ruminant, cardenolides

Intoxicación accidental con *Nerium oleander* en lechería caprina en la Región Metropolitana de Santiago en Chile

Resumen

En establecimiento de pequeño productor caprino (n = 52) en la zona central de Chile, se les administraron en comederos plantas ornamentales y pastos que fueron obtenidos posterior a la poda de jardines en sectores aledaños. A las 12 horas post ingesta de este alimento se encuentran 8 caprinos, hembras, adultos, productivos muertos previo al ingreso a sala de ordeña. El episodio de mortandad se extendió por 84 horas generando una mortalidad del 48 % y una morbilidad del 52 %. Se realizó visita, inspección clínica, necropsia y análisis microscópico de especímenes fijados en solución formolada taponada al 10 %. La inspección clínica confirma la presencia de animales con afección cardiovascular, al igual que el análisis microscópico. Las lesiones son compatibles con las producidas por glucósidos cardiotóxicos, al recorrer el lugar se observa la presencia de *Nerium oleander* en comederos de lote afectado, lo que sugiere la intoxicación de

* Artículo resultado de investigación.

- 1 Veterinarian. Spc. Animal Health, Laboratorio de Patología Veterinaria Universidad Mayor, Santiago de Chile. ✉ carlos.flores@umayor.cl; flores.carlos.vet@gmail.com <https://orcid.org/0000-0002-7837-3849>
- 2 Veterinarian, School of Veterinary Medicine, Faculty of Sciences, Universidad Mayor, Santiago de Chile.
- 3 Histotechnologist. Spc. Morphophysiology and cytodiagnosis, School of Veterinary Medicine, Faculty of Sciences, Universidad Mayor, Santiago de Chile.
- 4 Veterinarian, School of Veterinary Medicine, Faculty of Sciences, Universidad Mayor, Santiago de Chile.
- 5 Student of Veterinary Medicine, School of Veterinary Medicine, Faculty of Sciences, Universidad Mayor, Santiago de Chile.
- 6 Student of Veterinary Medicine, School of Veterinary Medicine, Faculty of Sciences, Universidad Mayor, Santiago de Chile.
- 7 Student of Veterinary Medicine, School of Veterinary Medicine, Faculty of Sciences, Universidad Mayor, Santiago de Chile.
- 8 Veterinarian, Master in Biomedicine, School of Veterinary Medicine, Faculty of Sciences, Universidad Mayor, Santiago de Chile.

How to cite this article: Flores Olivares C, Moraga Muñoz C, López Eldredge F, Pinto Morales J, Navarrete Figueroa L, Rodríguez Latorre C, et al. Accidental poisoning with *Nerium oleander* in dairy goat in the Santiago Metropolitan Region in Chile. *Rev Med Vet.* 2019;(39):43-48. <https://doi.org/10.19052/mv.vol1.iss39.4>

estos animales. La presencia de esta planta en la zona de la intoxicación es elevada y antes de nuestra visita no fue asociada al episodio de mortandad, lo que nos indica que se debe realizar capacitación e informar a productores sobre el manejo y alimentación de sus animales.

Palabras clave: *Nerium oleander*, glucosidos, pequeños rumiantes, cardenólidos

Intoxicação acidental com *oleandro de Nerium* em laticínios de cabras na região metropolitana de Santiago, no Chile

Resumo

No estabelecimento de um pequeno produtor de cabras (n = 52) na zona central do Chile, plantas ornamentais e pastagens foram administradas em alimentadores que foram posteriormente podados por jardins em setores próximos. Às 12 horas após a ingestão deste alimento, são oito cabras, fêmeas, adultos, mortos produtivos antes de entrar na sala de ordenha. O episódio da morte prolongou-se por 84 horas, gerando uma mortalidade de 48% e uma morbidade de 52%. Foram realizadas visita, inspeção clínica, necropsia e análise microscópica das amostras fixadas em solução formolada tamponada a 10%. A inspeção clínica confirmou a presença de animais com doença cardiovascular e a análise microscópica. As lesões são compatíveis com as produzidas pelos glicosídeos cardiotoxicos, ao atravessar o local, observa-se a presença de oleandro de *Nerium* nos alimentadores do lote afetado, o que implica na intoxicação desses animais. A presença desta planta na zona de envenenamento é alta e, antes da nossa visita, não estava associada ao episódio da morte, o que indica que o treinamento deve ser realizado e informa os produtores sobre o manuseio e a alimentação de seus animais.

Palavras-chave: *oleandro de Nerium*, glicosídeos, pequenos ruminantes, cardenólidos.

INTRODUCTION

Nerium oleander is an ornamental plant (Figure 1) that is potentially lethal and belongs to the *Apocynaceae* family (1). Its primary cytotoxic components are digitoxigenin, folinerin, neriin, rosagenin, and oleandrin, which are cardiac glycosides of vegetal origin with a glycolipid nature (2, 3, 4, 5). Due to their perennial foliage, these toxic molecules are present throughout the year and are found on stems, flowers, and leaves, both dry and green (6, 7). Reports of poisonings have been described in several species, such as geese, horses, dogs, and bears (8, 9, 10, 11, 12). However, the frequency and severity of mortality have been mostly studied in ruminants due to their production system and accessibility, with reported mortalities between 41-100 % (1, 13, 14). *N. oleander*

is described as an unpalatable plant because it releases a type of triterpenoid glycoside (saponins) when the fresh leaves are chewed, which produces an unpleasant burning sensation on contact with the oral mucosa (15). However, it can be consumed voluntarily by animals when they are hungry (16) or during periods of prolonged drought since oleander is one of the few species available because it is a highly resistant perennial plant (3). Nevertheless, the palatability of its leaves improves after they are detached from the bushes, pruned, or treated with herbicides, which makes them more likely to be consumed voluntarily. There are reports of accidental poisonings after consuming dry leaves intermixed with grass, bales, and/or rolls of hay since the toxicity of the plant is maintained for prolonged periods (1, 3).

Figure 1. *Nerium oleander* in the summer; its toxicity is due to its primary cytotoxic components such as digitoxigenin, folinerin, neriin, rosagenin, and oleandrin.



Source: own work

The purpose of this case report is to reveal an episode of mortality in dairy goats due to the consumption of *N. oleander* administered by the feedlot manager. This form of poisoning is classified as atypical because the animals were in corrals, and this was the only forage resource available to them, so they were forced to ingest it regardless of its low palatability. The authors have no knowledge of poisoning by the plant in this locality, which mainly supports goat production. Workers, technicians, and veterinarians must recognize it and eliminate it from the animal's diet.

MATERIALS AND METHODS

In the town of Peldehue that is located in the Metropolitan Region of Santiago, Chile ($33^{\circ}10'17''S70^{\circ}37'53''O$), a mortality episode of adult goats kept for intensive dairy production was reported during the summer. Those affected were fed with remains of pruned trees and ornamental plants in an area close to the farm. At 12 hours' post-ingestion (pi), it was reported that 15 % of the animals that had access to this trough were found dead (Figure 2), and 11 % had clinical signology. Mortality lasted 84 hours, at which time a visit was requested. Autopsies of the animals were performed on-site, and the person in charge indicated weakness, sternal decubitus, and increased heart rate. Several tissue fragments were extracted from the heart, lung, kidney, lymph node, and digestive system, including rumen, reticulum, omasum, abomasum, duodenum, and jejunum, which were fixed with 10% buffered formaldehyde. These fragments were processed with routine protocol and included in paraffin, from which cuts of 4-5 microns thick were obtained, stained with Hematoxylin and Eosin and observed under an optical microscope. Corrals were visited in order to visually analyze the type and species of plants available in the trough.

Figure 2. Adult female goats found dead 12 h after ingesting feed that was administered in troughs.



Source: own work

RESULTS

It was determined that 54% of the flock showed clinical signs that include agalactia, apathy, sternal decubitus, severe dehydration, anorexia, and/or cranial pressure (Figure 3). The autopsy findings revealed pale areas without clear limitations and a slightly elevated level of ventricular myocardium and papillary muscles on the left side. Both lungs showed an increase in their touch consistency and a presence of foam in the bronchial bifurcation and first tracheal portion. They also showed marked ruminal and abomasal distension with solid content and a fibrous aspect with remains of leaves that could not be identified at that time, as well as petechiae, hemorrhage in the abdominal serosa, duodenal mucosa, and the first portion of jejunum with marked congestion and slightly thickened walls and edematized in the first duodenal portion and its lumen. The large intestine presented greenish to brown content of low liquid consistency as well as reddened and enlarged mesenteric lymph nodes (twice its normal size).

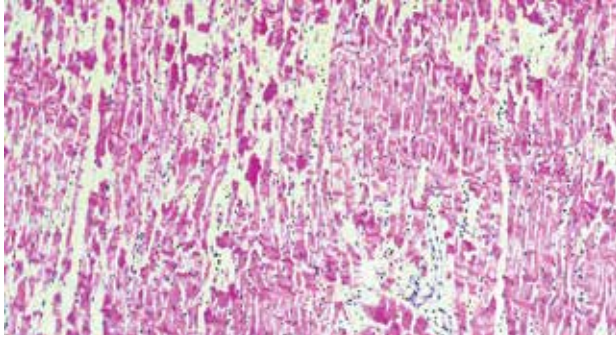
There were no alterations in size and morphology at the hepatic level. Histopathological lesions included marked multifocal necrosis of contractile myocardocytes with heterogeneous coloration, pale and eosinophilic areas, pyknotic nucleus, rupture of myofibrils, mild lymphoplasmacytic infiltration, incipient fibrosis areas in more affected areas, and structures compatible with *Sarcocystis spp* (Figure 4 A-B). In the lung, edema and mild diffuse interstitial hemorrhage were found. In the kidney, interstitial hemorrhage and mild tubular degeneration with the presence of intraluminal cell debris were found. In the reticulum, rumen, omasum, and abomasum, mild mononuclear inflammatory infiltrate, hyperemia, congestion, and bleeding in the lamina propria were also noted. Hepatocytes, hydrophilic and vacuolar degeneration was found in the centrilobular area. During the inspection of the farm, *N. oleander* leaves were found mixed with the other forage in the troughs. Some of them were green while others were dry, and they showed evident marks of having been chewed.

Figure 3. Adult female goat, which presents loss of body condition, respiratory difficulty, and skull pressure 84 h post-ingestion of feed administered in troughs



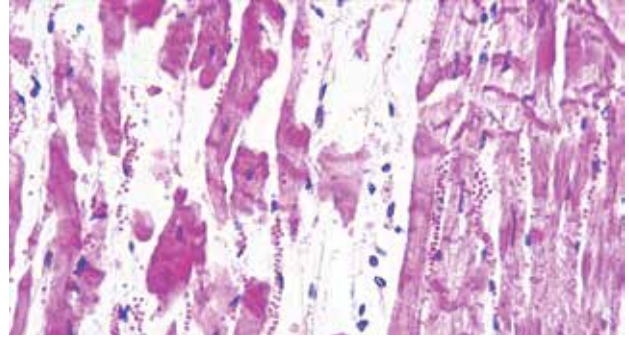
Source: own work

Figure 4. A-B: Histological sample of the heart: (A) Moderate to severe multifocal myocardial necrosis with myocardiocytes of hypereosinophilic cytoplasm and picnosis. Loss of continuity of myofibrils and areas of mild to moderate mononuclear inflammatory infiltrate (H&E, 10X) (B) Contractile myocardiocytes with hypereosinophilic cytoplasm, marked picnosis, and occasional absence of nucleus (H&E 40X).



Source: own work

A



B

DISCUSSION

N. oleander is not a plant that the animals consume voluntarily but, as indicated (1,15), some factors make poisoning occur accidentally. One of them is that the leaves and branches of oleander were pruned, which made them palatable, and in this case, the leaves were mixed with forage that facilitated accidental consumption. It was administered in the ration because those in charge lacked knowledge about the plant's toxicity. Although accidental cases have been reported in cattle (1, 7), the cases analyzed in small ruminants only refer to experimental poisonings in which variable doses ranging from 0.05-1 g/Kg have been administered, with episodes of mortality starting at 4 hours and lasting up to 8 days (17, 18). As reported by other authors (6), it is not possible to determine the value of the lethal dose 50 (LD50). However, it is possible to determine with certainty that the temporal range of mortality began at 8 hours (pi) and was extended until 84 hours, coinciding with those reported. As in the present report, the literature indicates that clinical signology primarily affects the cardiovascular system, then the respiratory, renal, digestive, and central nervous systems (18). In the cardiovascular system, this is due to the tropism of the cardenolides by the cardiomyocytes, which act by binding and inhibiting the Na^+/K^+ -ATPase pump present in the membrane

that causes an electrolyte imbalance consisting of an increase in extracellular K^+ and intracellular Na^+ . Due to the latter's increase, the functioning of the $\text{Na}^+/\text{Ca}^{2+}$ ion-exchange channel is disrupted and an increase in intracellular Ca^{2+} is generated, which leads to a markedly positive inotropic effect. It also generates macroscopically necrosed areas and marked multifocal necrosis of contractile myocardiocytes upon histopathological examination, as described by other authors (6, 7, 19). The increase in Ca^{2+} causes the modification of the resting membrane potential, increasing its positivity and generating spontaneous depolarizations (6). The main effect on the respiratory system was the discovery of bronchial and tracheal edema, as well as other cases studied in other species (7). These glycosides also generate necrosis in renal tubular epithelial cells, which is more evident in distal contoured tubules and collectors (18). In this case, the lesions reported were interstitial hemorrhage and mild tubular degeneration with the presence of intraluminal cellular debris, coinciding with the findings of other authors (6). According to other cases (18), oleandrin can cross the blood-brain barrier and accumulate in the central nervous system, which explains the signology of cranial pressure in one of the clinically affected animals. There are also reports of histopathological lesions such as cerebral hemorrhage and congestion (17), which were not observed in this case.

CONCLUSIONS

The presence of the plant, the evolution of mortality, clinical signology, macroscopic, and microscopic findings suggest that accidental poisoning was due to *N. oleander* in this farm and knowledge of this plant species is essential to arrive at a confirmatory diagnosis.

REFERENCES

- Fazzio L, Costa E, Mattioli G, Idiart J. Intoxicación natural por laurel de jardín (*Nerium oleander*) en bovinos descripción de un caso. Red Med Vet. 2007; 88(6): 261-5. Retrieved from http://www.produccion-animal.com.ar/sanidad_intoxicaciones_metabolicos/intoxicaciones/171-laurel_261.pdf
- Caloni F, Cortinovis C. Plants poisonous to horses in Europe. Equine Vet J. 2015; 27(5): 269-74. <https://doi.org/10.1111/eve.12274>
- Langford S, Boor P. Oleander toxicity: an examination of human and animal toxic exposures. Toxicology. 1996; 109(1): 1-13. [https://doi.org/10.1016/0300-483x\(95\)03296-r](https://doi.org/10.1016/0300-483x(95)03296-r)
- Karawya M, Balbaa S, Khayyal E. Estimation of cardenolides in *Nerium oleander*. Planta Med. 1973; 23(1): 70-3. <https://doi.org/10.1055/s-0028-1099414>
- Kumar A, De T, Mishra A, Mishra. A. Oleandrin: A cardiac glycosides with potent cytotoxicity. Pharmacogn Rev. 2013; 7(14): 131-9. <https://doi.org/10.4103/0973-7847.120512>
- Aslani M, Movassaghi A, Janati-Pirouz H, Karazma M. Experimental oleander (*Nerium oleander*) poisoning in goats: a clinical and pathological study. Iran J Vet Res. 2007; 8(1): 58-63. <https://doi.org/10.22099/IJVR.2007.2708>
- Galey F, Holstege M, Plumlee K, Tor E, Johnson B, Anderson M, Blanchard PC. Diagnosis of oleander poisoning in livestock. J Vet Diagn Invest. 1996; 8(3): 358-64. <https://doi.org/10.1177/104063879600800314>
- Alfonso H, Sánchez L, Merino N, Gómez B. Intoxication due to *Nerium oleander* in geese. Vet. Hum. Toxicol. 1994; 36(1):47. Retrieved from <https://www.ncbi.nlm.nih.gov/pubmed/8154101>
- Mahin L, Marzou A, Huart A. A case of *Nerium oleander* poisoning in cattle. Vet. Hum. Toxicol. 1984; 26(4): 303-4. Retrieved from <https://www.ncbi.nlm.nih.gov/pubmed/6540502>
- Ratigan W. Oleander poisoning in a bear. J. Am. Vet. Med. Assoc. 1921; 60, 96-8.
- Trautvetter E, Kasbohm C, Werner J. Oleander poisoning with respiratory AV block in a dog. Berl. Munch. Tierarztl Wschr. 1969; 82(16): 306-8. Retrieved from <https://www.ncbi.nlm.nih.gov/pubmed/5389705>
- Williams B. Oleander poisoning in a group of calves. Southwestern Vet. 1957; 10, 151-2.
- Panisset L. Noxiousness of Rhododendron (oleander) sprouts. North Am. Vet. 1923; 4, 255-6.
- Soto-Blanco B, Fontenele-Neto J, Silva D, Reis P, Nóbrega E. Acute cattle intoxication from *Nerium oleander* pods. Trop Anim Health Prod. 2006; 38(6): 451-4. <https://doi.org/10.1007/s11250-006-4400-x>
- Mack R, To see a world in a grain of sand and a heaven in a wild flower. oleander poisoning. Nc Med J. 1984; 729-30. Retrieved from <https://www.ncbi.nlm.nih.gov/pubmed/6595534>
- Al-Farwachi M, Al-Badrani B, Rhaymah M. Acute toxicity of *Nerium oleander* aqueous leaf extract in rabbits. Iraqi J vet sci. 2008; 22(1): 1-4. Retrieved from <http://agris.fao.org/agris-search/search.do?recordID=DJ2012044005>
- Adam S, Al-Yahya M A, Al-Farhan A. Acute toxicity of various oral doses of dried *Nerium oleander* leaves in sheep. Am J Chin Med. 2001; 29(3-4): 525-32. <https://doi.org/10.1142/S0192415X01000551>
- Barbosa R, Fontenele-Neto J, Soto-Blanco B. Toxicity in goats caused by oleander (*Nerium oleander*). Res Vet Sci. 2008; 85(2): 279-81. <https://doi.org/10.1016/j.rvsc.2007.10.004>
- Pedroso P, Bandarra P, Bezerra Júnior P, Raymundo D, Borba M, Leal J, Driemeier D. Intoxicação natural e experimental por *Nerium oleander* (Apocynaceae) em bovinos no Rio Grande do Sul. Pesq. Vet. Bras. 2009; 29(5): 404-8. Retrieved from <http://www.scielo.br/pdf/pvb/v29n5/08.pdf>